

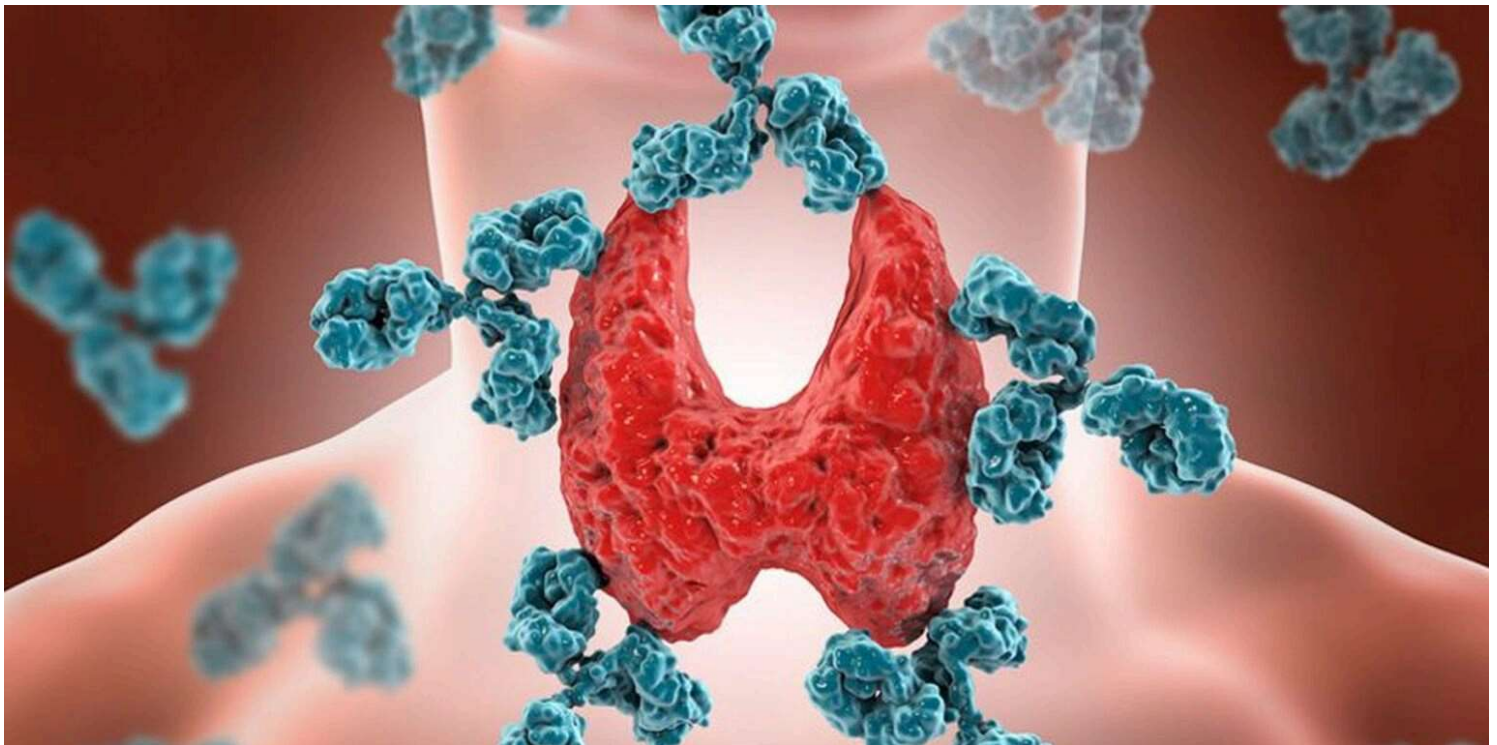
**Hpathy**

Leading Holistic Health Portal: Since 2007

**Hpathy Needs
Your Support..**[PROFESSIONAL](#) ▾[ENGAGE](#) ▾[EJOURNAL](#)[EBOOKS](#)[DISEASES](#)[SUBSCRIBE: JOURNAL](#)[BOOKS](#)[COURSES](#)

Clinical Cases

Sub-Acute Thyroiditis Post Covid-19

April 19, 2022 · [Add Comment](#) · by [Rajiv Peres](#)

Dr. Rajiv Peres shares a case of post Covid Sub-Acute Thyroiditis in a man of 46. The patient presented with severe burning from right ear to the neck.

**submit paper for
publication**

Low publication
charge with
certificate in
Peer-reviewed
Refereed
Journals

On 16th August, 2021 A 46- year- old male, who works as helper in the fabrication workshop presented with complaint of pain in right ear extending down to the lower aspect of right side of the neck since June 2021. He was unable to swallow his food normally for the last 15 days.

He complained of severe burning from right ear to the neck with sensation as if someone is eating his ear. He wanted to have a cold rain water bath. He could not tolerate any noise and got very irritated, wanting to beat his children when they made noise.

He would feel tired easily while speaking. His voice was weak and I could not understand his words, since articulation was indistinct and forced. He spoke hastily and there was a considerable amount of shortness of breath. He would get fever in the evenings at 4pm with chills, heat and body ache for the last 4 months.

Since Covid in April 2021 there was aching pain in both calf muscles and his body felt shaken up the last 15 days (beginning of August 2021). After suffering from Covid his thermal state had changed to his being a chilly patient.

Two months ago in April 2021, he had headaches and body aches, vertigo < talking associated with chest discomfort and was diagnosed as Covid positive.

In July 2021 he had severe pain in the right ear and neck, was getting fever on a daily basis and he could not go to work. In end of July 2021, he visited the local health centre's ENT O.P.D and an ultrasound was done which revealed Multinodular Goitre with ill-defined nodule in right lobe.

At the same time his T3 level was raised (2.47ng/dl), T4 was raised (17.6ug/dl) and TSH was low (0.02uIU/ml. On physical examination the neck swelling was visible.

Physical Generals:

Appetite: Doesn't like to eat although hungry; he had a salty taste in his mouth. Since he was on antipyretic medicines for fever, he had a running nose which relieved him partly.

Cravings: He loves ice creams and custard and cakes. However, at present he avoids it consciously.

Stool: Constipated since last 15 days, scanty stool. Earlier he use to pass stools thrice a day.

Sleep: Disturbed by dreams. In dreams he would see that somebody had caught his throat. He also had a dream that he was discussing and trying to identify his mysterious sickness.

Thermals: Chilly patient

He had become impatient and angry due to months of suffering from fever, no work, no diagnosis and the whole family was afraid that he had cancer. In his locality three people had been found to be suffering from cancer, and this frightened his family all the more. He was an honest, well-behaved man but at his

See also

Revisiting: Polio Party!

Anamnesis of the case:

The first issue was to correctly diagnose the case, hence I decided to refer this patient immediately to endocrinologist Dr. Newman Correa. Dr Newman advised a Radio Isotope scan done on 11th August 2021 which confirmed that it is not malignancy but thyroiditis.

He prescribed some painkillers and the patient began feeling better. I knew that this relief would be short lived. Exactly 5 days later, the patient presented with neck and ear pains to my out-patient department. I thought that we should prescribe something befitting his present state of inflammation.

When I examined his enlarged thyroid, the right side felt spongy. I referred to Kent's Repertory – External Throat Goitre, Right and Goitre Painful. I had to select between Iodium and Spongia. I decided to prescribe Spongia because in Spongia the thyroid enlargement is spongy and secondly in concordant Materia Medica of Frans Vermeulen it is written that "Toasted sponge contains a small percentage of Iodine".

Thirdly, the pace of slow onset of symptoms of Spongia matched the description of the patient's symptoms as described by Dr J.T Kent, like for example the night aggravation and also the marked anxiety and fear of death with suffocation.

The 1st prescription was given on 16th August 2021 – **Spongia 30**, three times a day for five days. One may call this a pathological prescription or a phase remedy.

Follow up on 23rd August 2021 – The patient said that immediately on the first day of starting Spongia he got a fever. He usually got a fever 4-6 pm but this time it was rather 6-8pm. He did not take any antipyretic, and then on day two after commencing taking Spongia, no fever but he started with coryza that was thick, yellow and he felt relieved every time it was discharged.

The severe burning pain in throat was 100% relieved. The breathlessness also improved but was not completely back to normal. He was able to resume his work at the workshop from 23rd August 2021. No prescription.

See also

A Case of Autism

Follow up on 30th August 2021– Patient returned with complaint of burning pain radiating from left ear down to left lobe of thyroid (old symptom which was there at the time he contracted Covid in April 2021). He had developed strong craving for ice cream since 29th August 2021. No prescription was given

suffered from pains in left leg since last 8 days probably due to over working.

He had to strain to pass stools. He had breathlessness after exercise. He would also feel slightly giddy, better after eating sweets. Craving for ice cream was very marked. Here we took the opportunity to prescribe his constitutional remedy – **Phosphorus 30** (second prescription), twice a day for three days.


Follow up on 13th September 2021 – In the first 3 days of beginning Phosphorus 30 the left ear pains were 80% relieved. Thereafter in between, the pains returned and disappeared especially while riding his motorbike. Better by inserting cotton in to the ears.

Then his right ear pained. The pain in left side of thyroid was present when the ear pains appeared and also during sneezing. However, the pain was not continuous as before. After starting Phos 30 the constipation improved. Breathlessness which was during eating improved 10%. No giddiness. Craving for ice cream still persisted but avoids eating it. Left leg pain is okay. Overall he feels less afraid. He can even do mental work which he was avoiding all this time. No medicine was given.

Follow Up on 29th November 2021 – Patient had a follow up visit with endocrinologist and all his thyroid readings were in normal limits. No conventional medicine was prescribed. Homeopathically also no medicine was prescribed. No burning, no giddiness, no constipation. no craving for ice creams.

This case shows us that constitutional medicine will bring all the good if given at the right time. Although we were able to identify Phosphorus symptoms during the first visit, it would not have been correct to prescribe it, since the thyroid gland inflammation was more striking and Phosphorus had little role to act there. Homoeopathy displayed it precision in totally curing this case of thyroiditis.

You may also like



Autism and ADHD in a Child of 3



Severe Shingles Followed by

Homeopaths Prajakta Vaidya and Preeti Shah-Chauhan present a case of autism with ADHD in a three...

Homeopath Gina Tyler shares a case of severe shingles followed by postherpetic neuralgia in a woman...

Homeopathic Trauma

January 20, 2010 • by [Maria T. Bohle](#)

A trauma case in which quick application of a high potency homeopathic remedy saved a life.

About the author



Rajiv Peres

Dr. Rajiv Rui Viegas Peres M.D(Hom) Associate Professor, Dept of Organon of Medicine, Aarihant Homoeopathic Medical College, Bhoyan Rathod, Gandhinagar, Gujarat. Pin 382721
Received Best Teacher's Award 2010-11, Received Hahnemann Award 2018, Received Excellence in Homoeopathy Award in April 2022, Active Member of H.E.R.I Mumbai.

[View all posts](#)

Leave a Comment

Comment

Name *

Email *

Website

I'm not a robot

reCAPTCHA
[Privacy](#) - [Terms](#)

Post Comment



[About Us](#) | [Terms of Service](#) | [Privacy Policy](#) | [Disclaimer](#) | [Copyright Notice](#) | [Author Guidelines](#) | [Contact](#)

Copyright © 2024. Hpathy Medical Publishers